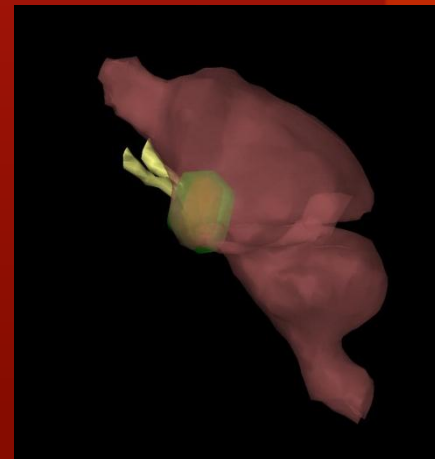
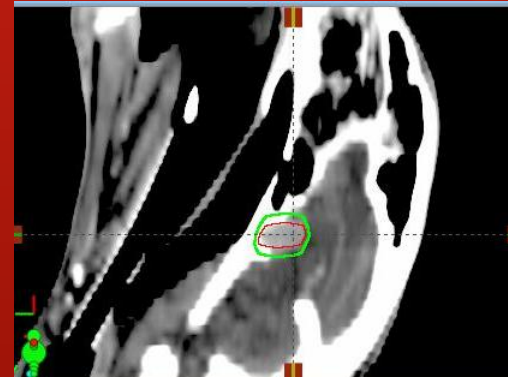
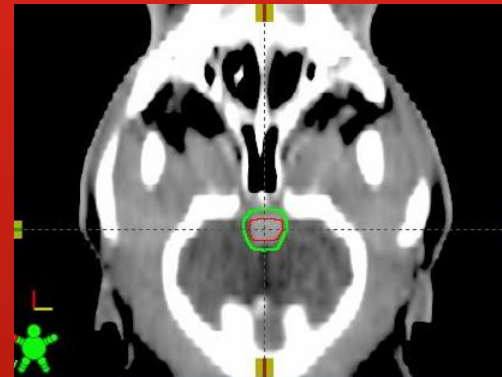
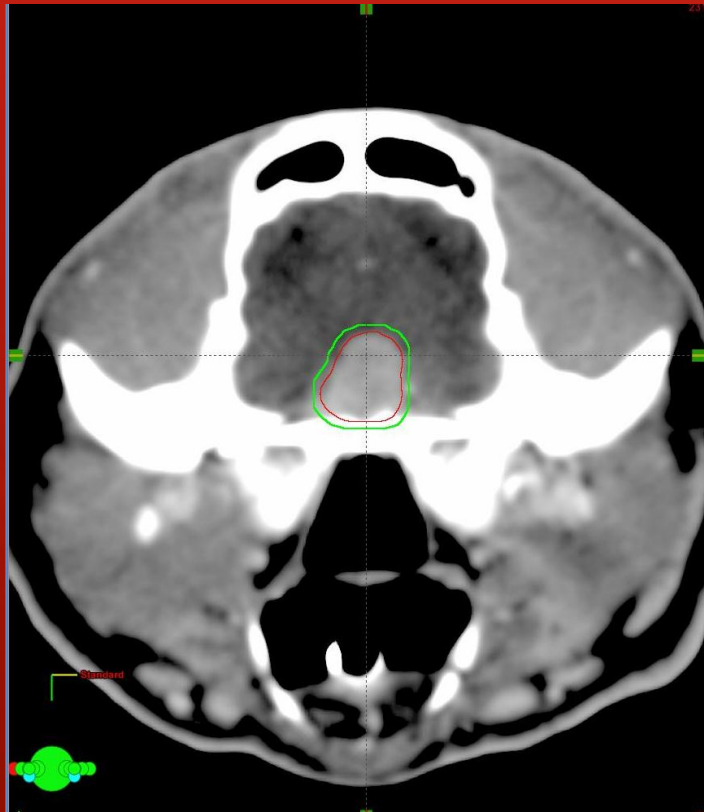
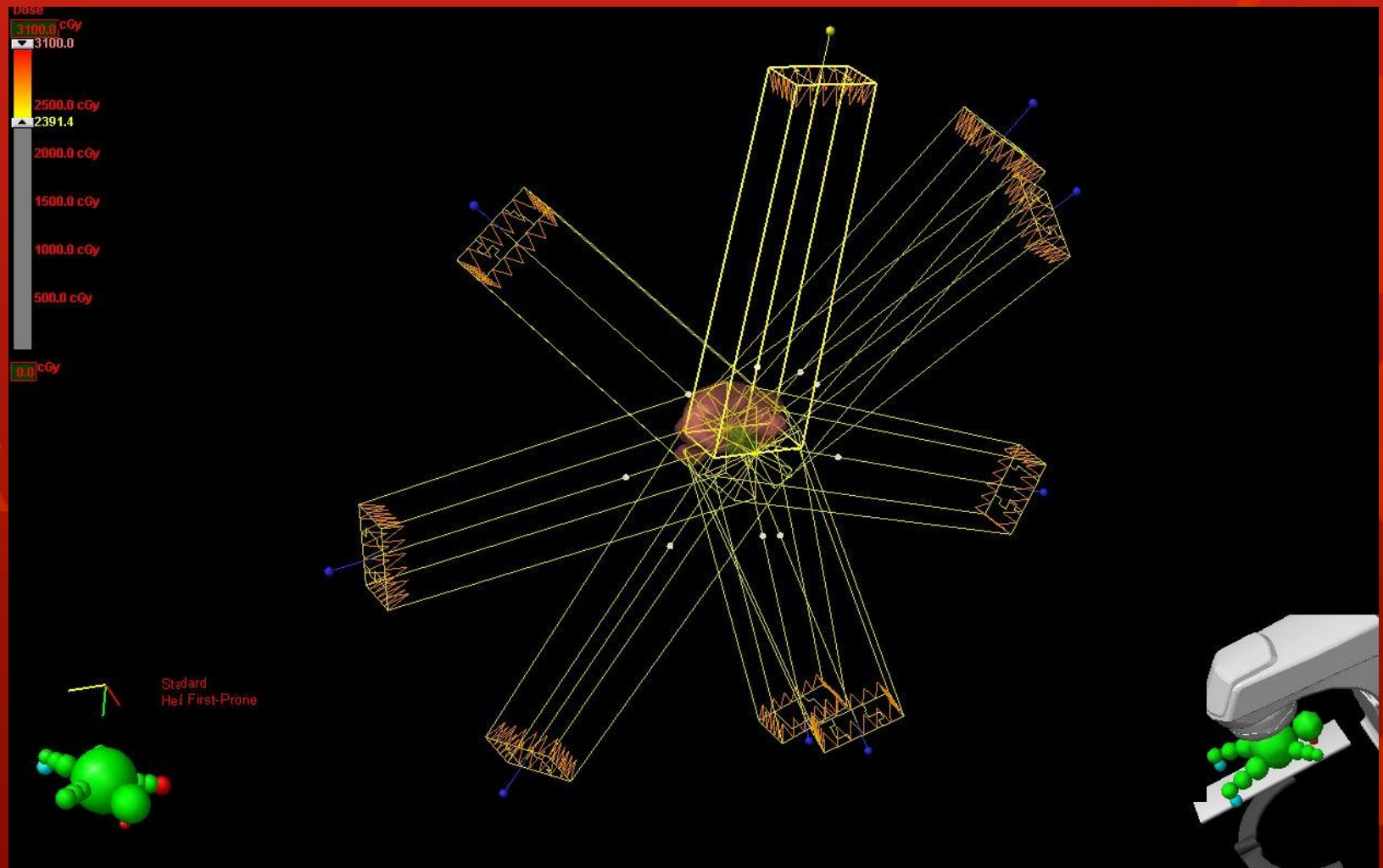


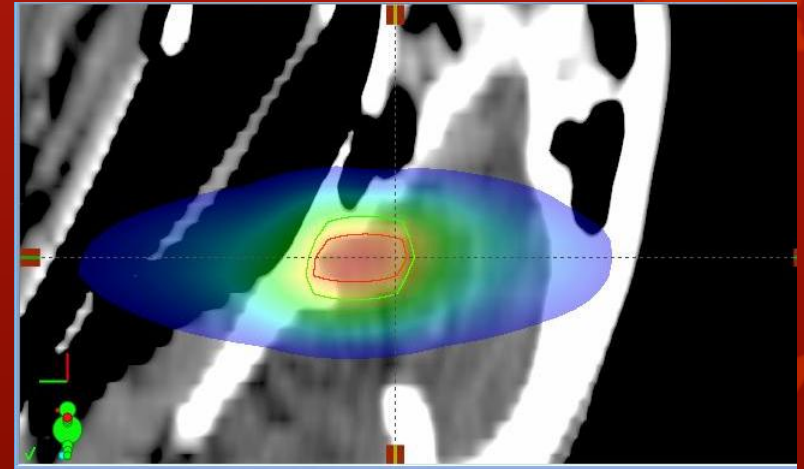
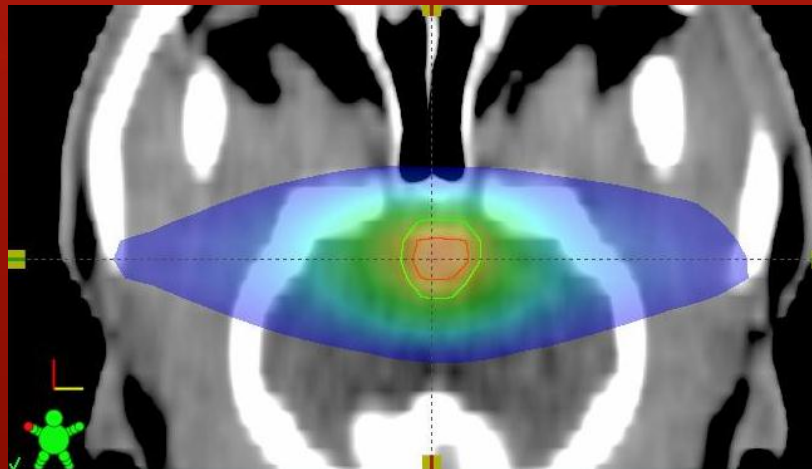
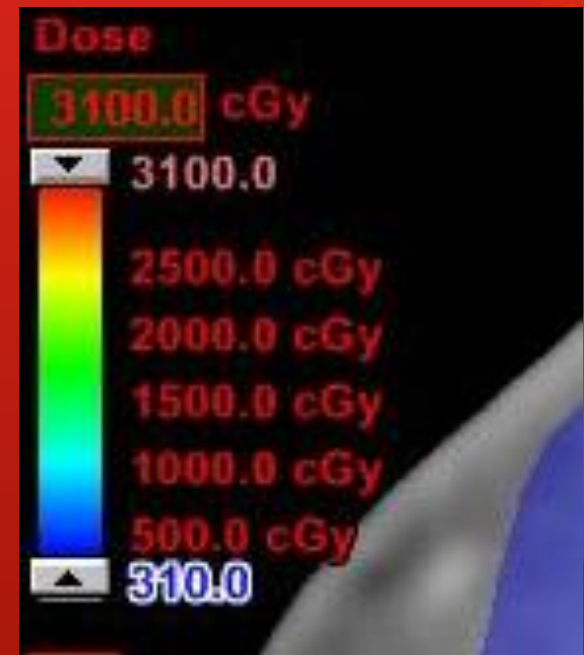
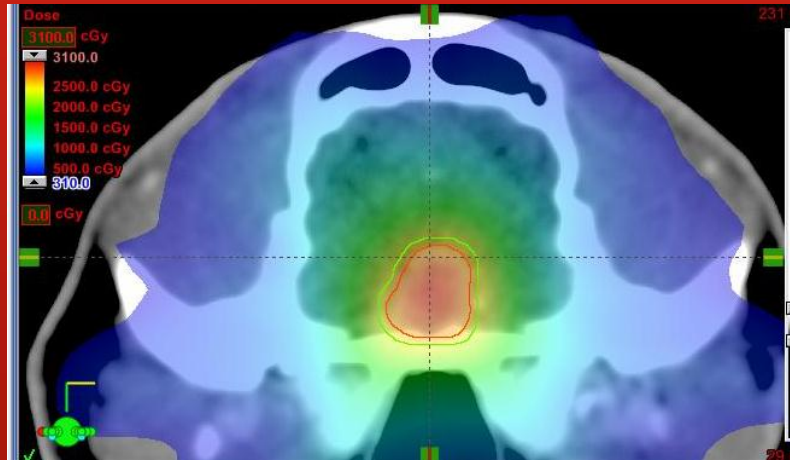
Radiation Planning...



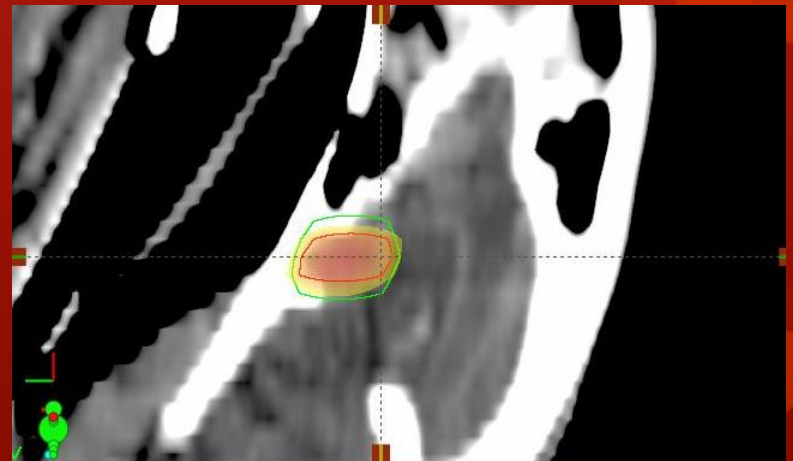
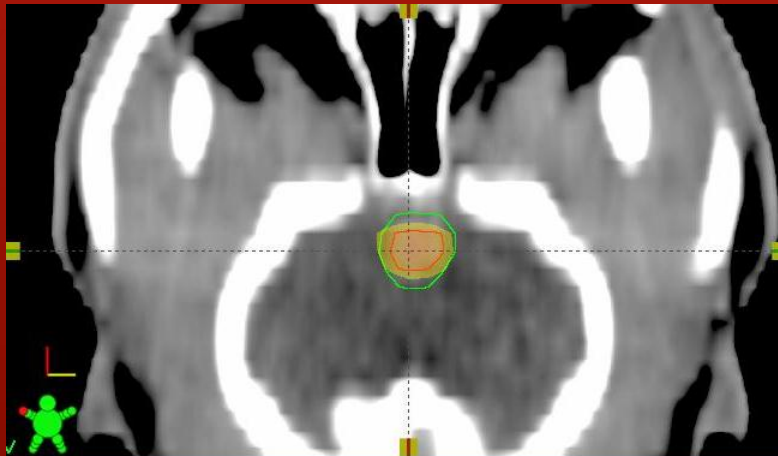
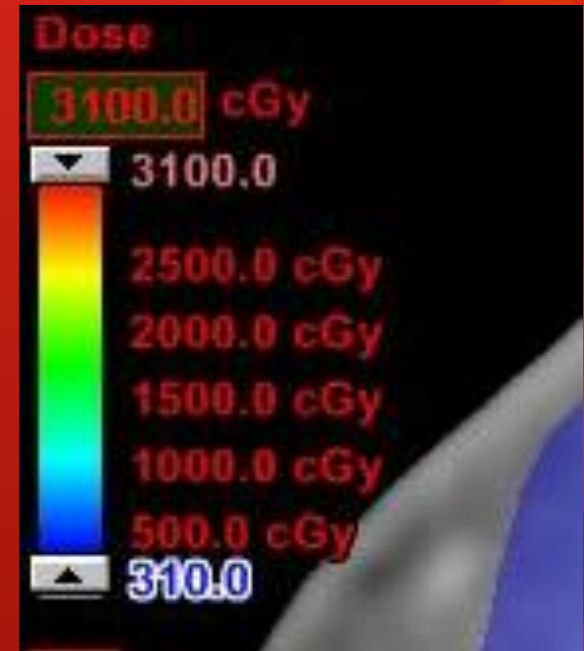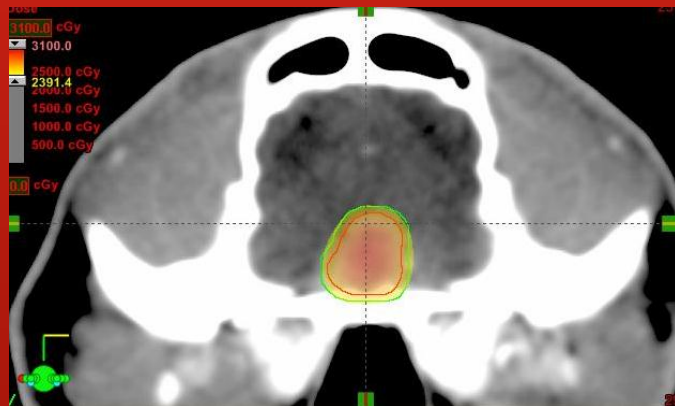Radiation Planning



Dosing



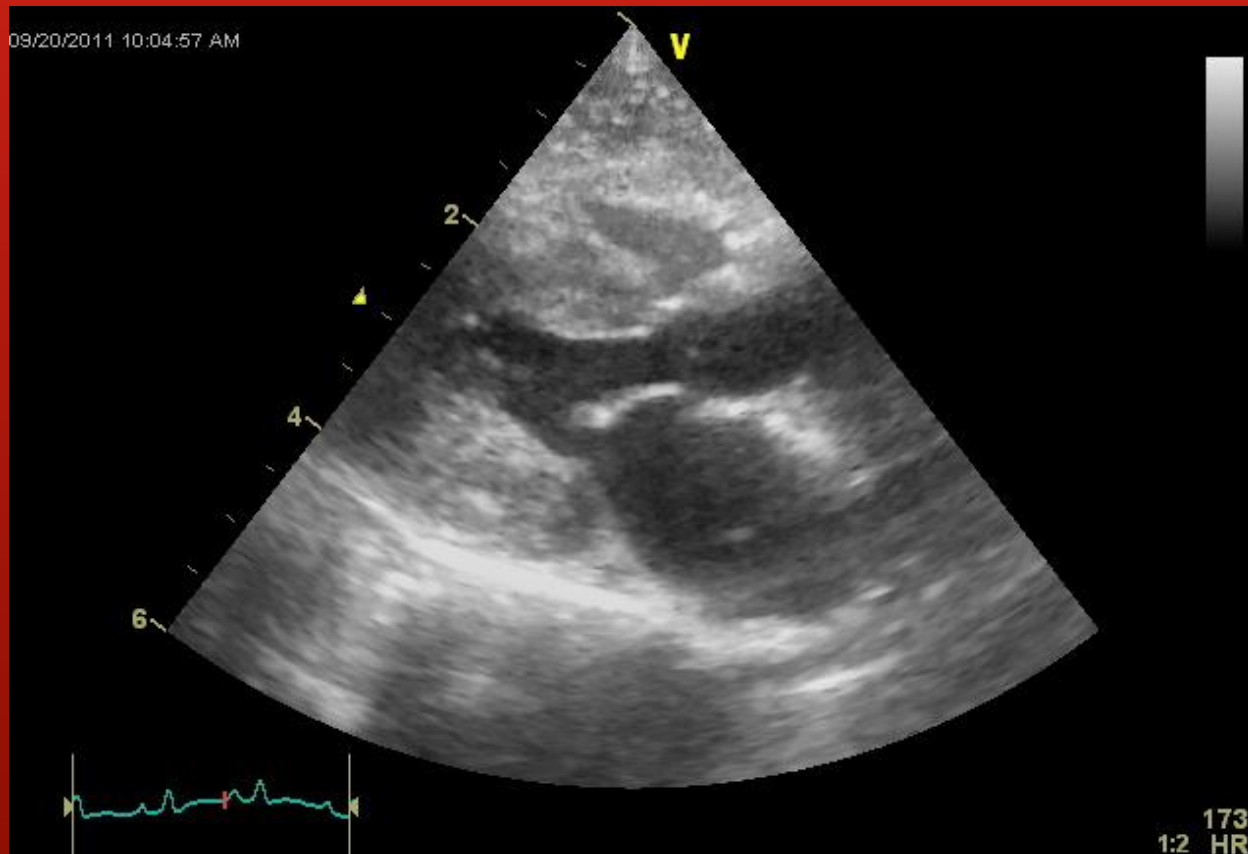
Radiation Planning...



9/20/11 – Get Echocardiogram and Start Radiation Therapy

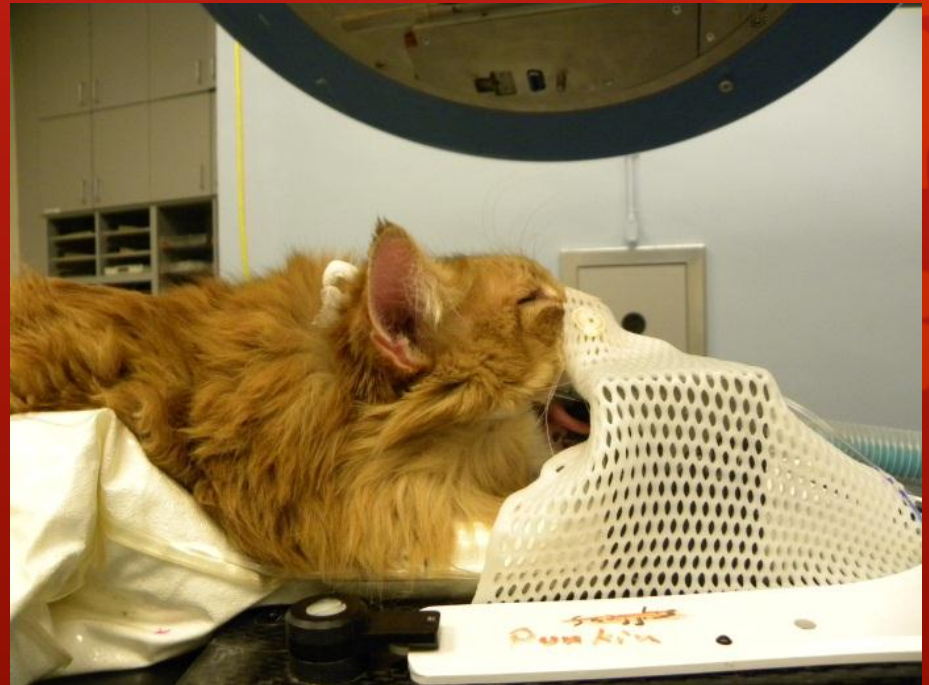- Physical Exam:
 - T – 97.4ax P – 200 R – 36
 - Weight – 6.3kg
- Did well overnight while recovering from anesthesia
- Echocardiogram : Left Atrial Enlargement
 - Mildly Enlarged Left Atrium – 18.1mm (N 7.0 – 17.0)
 - Mildly Enlarged Septum – 10.1mm (N 4.0 – 9.0)

Echocardiogram



Let the Radiation Begin

- 3 fractions of Stereotactic Radiation
- Each fraction of 8 gy
- Total of 24 gy
 - To get the most amount of radiation into tumor



3rd and final dose on 9/22/11

- Eyes remained dilated at home after first dose but normalized after second
- Physical unremarkable.
- Got final dose of SRT bringing him to his total of 24 gy
- Went home on prednisone 5mg once daily for side effects of radiation

